



## DISORDERS RELATED TO NUCLEAR FACTOR KAPPA B ESSENTIAL MODULATOR (NEMO) IMMUNODEFICIENCY IN CHILDREN: A REVIEW

Harbola Priyanka\*, Mishra Pragya

Devsthali Vidyapeeth College of Pharmacy, Kiccha road, Lalpur, Rudrapur (U.S. Nagar), Uttarakhand, India

Article Received on: 18/03/12 Revised on: 29/04/12 Approved for publication: 15/05/12

\*Email: priyanka\_harbola@yahoo.com

### ABSTRACT

IKBKG is a gene that encodes for a protein which regulates nuclear factor kappa-B (NF-KB). This NF-KB not only plays an integral role in body's inflammatory and immune responses but also affects ectodermal development. The protein complex NF-KB is present in the cytoplasm in an inactive form and requires nuclear factor kappa-B essential modulator (NEMO) for its activation. Impaired expression of NEMO, therefore, results in immunodeficiency. This article throws light on the three major disorders that occur in children due to mutations in NEMO. The disorders include ectodermal dysplasia, incontinentia pigmenti and osteopetrosis. Ectodermal dysplasia involves dystrophies of the ectodermal structures causing hypohidrosis, hypotrichosis etc. Incontinentia pigmenti mainly affects the skin but teeth, bones, brain and eyes are also not left unaffected in certain cases. Osteopetrosis targets the bones.

**KEYWORDS:** Immunoreceptors, Nuclear factor kappa-B (NF-KB), Incontinentia pigmenti, Ectodermal dysplasia, Osteopetrosis

### INTRODUCTION

IKBKG is the official symbol of a gene that encodes for a protein which is essential for regulating nuclear factor kappa-B (NF-KB). The NF-KB is a protein complex which is involved in body's inflammatory reactions and immune responses. It produces its effects by expressing chemokines, cytokines, immunoreceptors, growth regulators and cell adhesion molecules. It also plays a critical role in controlling those signals that cause a cell to undergo apoptosis or programmed cell death.<sup>1</sup>

NK-KB is present in the cytoplasm in an inactive form. It is complexed with an inhibitory protein called IKB. This NK-KB-IKB complex is activated by IKB kinase which possesses the regulatory subunit known as nuclear factor kappa B essential modulator (NEMO). The activation involves interaction of IKBKG proteins with two enzymes namely, IKK $\alpha$  and IKK $\beta$ . Upon activation, NF-KB moves into the nucleus for binding to DNA and in this manner NF-KB regulates the functioning of multiple genes.<sup>2,3</sup>

The activation of NF-KB can be inhibited by many pharmacological agents like tacrolimus, glucocorticoids, aspirin and deoxyspergualin. Glucocorticoids inhibit NF-KB by directly associating with NF-KB or by up-regulating IKB expression. Cyclosporine and tacrolimus prevent NF-KB activation by inhibiting the action of calcineurin, a phosphatase that indirectly induces IKB degradation. Deoxyspergualin inhibits NF-KB by blocking its nuclear translocation. Aspirin and salicylates inhibit upstream events inducing IKB phosphorylation. Tepoxalin and antioxidants inhibit NF-KB activation by influencing the redox state of the cell.<sup>4</sup>

NF-KB, a key transcription factor not only regulates innate and adaptive immunity but also ectodermal development. Impaired expression of NEMO which helps activate NF-KB therefore results in immunodeficiency. Incontinentia pigmenti, a fatal condition of hemizygous male patients is caused by amorphic mutations in the X-linked nuclear factor kappa B essential modulator gene (NEMO) while hypomorphic mutations in male patients result in anhidrotic ectodermal dysplasia (EDA) with immunodeficiency.<sup>5</sup>

### Ectodermal Dysplasia (EDA)

The X-linked recessive ED also known as the Christ-Siemens-Touraine syndrome is the predominant form of ED comprising 80% of EDs. It affects mainly the males but women act as carriers for its inheritance. The incidence in male is estimated at 1 in 100,000 births, the carriers-incidence is probably around 17.3 in 100,000 women.<sup>6</sup> It is characterized by three main signs:

- Sparse hair (Atrichosis or hypotrichosis)
- Abnormal or missing teeth (anodontia or hypodontia) ; of major concern.
- Inability to sweat as a result of lack of sweat gland (anhidrosis or hypohidrosis)<sup>7</sup>

Ectodermal dysplasias are a group of disorders characterized by developmental dystrophies of ectodermal structures, such as hypohidrosis, hypotrichosis, onychodysplasia and hypodontia or anodontia. About 160 clinically and genetically distinct hereditary dysplasias have been cataloged.<sup>8</sup>

EDA or Ectodermal Dysplasia Anhidrotic is a type of ED (Ectodermal Dysplasia). The EDs are a heterogeneous group of disorders that affect the development of the ectoderm. Patients of ED have a normal life expectancy as well as intelligence but its diagnosis in the early childhood becomes important. This is because these patients lack sweat glands that may lead to hypothermia and brain damage in early infancy. Genetic counseling must therefore be rendered to families of such patients.<sup>9</sup> The National Foundation for Ectodermal Dysplasias is working with a mission to empower and connect people touched by ectodermal dysplasias through education, support, and research. In the 30<sup>th</sup> Annual National Foundation for Ectodermal Dysplasias National Family Conference held from July 21-23 2011 in Mascoutah,US, assistance was aimed to be provided to patients of ED and also to the research in this field.<sup>10</sup>

A study was conducted on a twelve-week old male patient with skin eruption, intertrigo, atopic like dermatitis, erythroderma, frontal bossing, periorbital wrinkling and a thickened, everted lower lip. His mother had a history of incontinentia pigmenti. He was seen to have leukocytosis with eosinophilia, absence of Ig A and very low

levels of Ig G and Ig M. His detailed study led to the conclusion that mutations in NEMO should be considered in male infants with recalcitrant seborrheic or atopic dermatitis like eruptions and intertrigo, especially when features of ectodermal dysplasia are present<sup>11</sup>. Early recognition and diagnosis are desirable, prior to the onset of manifestations of immunodeficiency. The related images are displayed in figures I and II.

A study presented a report on a boy with hypodontia caused by hypohydrotic ED who received dental implants at the age of 8 years and was found to be satisfied with the therapy<sup>12</sup>. The related pictures are shown in figures III and IV.

### **Incontinentia Pigmenti**

Mutations in IKBKG gene either prevent the formation of IKBKG protein or cause the production of a nonfunctional and abnormally small form of the IKBKG protein. The lack of this protein obstructs the activation of nuclear factor kappa B (NF- $\kappa$ B). Since NF- $\kappa$ B prevents a cell from undergoing self-destruction, the cell deprived of active NF- $\kappa$ B shows increased sensitivity to signals that trigger apoptosis. As a result of this abnormal cell death occur which likely causes the signs and symptoms of incontinentia pigmenti.<sup>13</sup>

Incontinentia Pigmenti (IP) is a severe X-linked genodermatosis that presents in females as the males die *in utero* prior to the second trimester. It is always associated with skin defects in the affected females. Four distinct dermatological stages characterize IP and these begin within two weeks after birth. These are:

Stage I- Vesicular stage: Blisters, inflammatory response and a massive eosinophilic granulocyte infiltration into the epidermis.

Stage II- Verrucous stage: verrucous hyperkeratotic lesions develop

Stage III- Lesions so developed disappear leaving behind hyperpigmented areas of skin due to accumulation of melanin.<sup>14</sup>

Stage IV- Occurs only in a fraction of patients (about 14%) and in this hypopigmentation is seen. 28% patients show only small, hairless, atrophic patches<sup>15</sup> that maybe anhidrotic<sup>16</sup>

Incontinentia pigmenti or IP is also known as Bloch Sulzberger syndrome. It is a rare x-linked, dominantly hereditary disorder of the developing organs and tissues of ectodermal and mesodermal origin.<sup>17</sup> The name derives from the incontinence of melanin in the superficial dermis during the third, pigmentary stage of the disease.<sup>15</sup> This rarely inherited genetic disorder may affect the central nervous system but some other areas may also be affected<sup>18</sup>. The most commonly affected areas are mentioned in table I.

It is a genetic disease with blisters that develop soon after birth on the trunk and limbs, then heal, but leave dark (hyperpigmented) streaks and marble-like whorls on the skin. (The name came from the erroneous idea that the skin cells were incontinent of pigment and could not contain it normally.) Other key features of IP include dental and nail abnormalities, bald patches, and (in about 1/3<sup>rd</sup> of cases) mental retardation. IP is an X-linked dominant with male lethality. The IP gene is in band q28 on the X chromosome. Mothers with IP have an equal chance of having a normal or IP daughter or a normal son. The IP sons die before birth.<sup>19</sup>

Incontinentia pigmenti has also been shown to be associated with idiopathic precocious puberty. An 11 year old girl at birth had discrete but linear vesiculobullous lesions on the arms and trunk and blisters on both sides of the head. After some months, hyperpigmented lesions developed over the

vesiculobullous lesions. She was studied and demonstrated a rare clinical association between incontinentia pigmenti and idiopathic precocious puberty.<sup>20</sup>

Macular ischemia is characteristic of incontinentia pigmenti and is often progressive. It is the initiating event of a typical vasculopathy, characterized by capillary remodelling and, occasionally, by neovascularization and tractional detachment of the retina.<sup>21</sup>

### **Diagnosis of Incontinentia pigmenti**

Every effort is being made to find new methods for the diagnosis of incontinentia pigmenti<sup>22</sup>. Some of the existing methods of differential diagnosis are given in table II.

The utility of molecular studies in incontinentia pigmenti patients was demonstrated by different workers. They agreed that having knowledge of the fact that mutations in NEMO are a cause of IP has helped improve genetic counseling for this disorder. They presented four families of IP in whom molecular studies established an unequivocal diagnosis in the affected daughters, and showed two mothers to be carriers, thus allowing accurate genetic counseling and prenatal diagnosis.<sup>23</sup>

A novel PCR approach for prenatal detection of the common NEMO rearrangement in incontinentia pigmenti has been proposed by Arnold Munnich *et al.* The aim of their work was to facilitate prenatal diagnosis of IP by devising a novel test for detection of the prevalent NEMO deletion. They devised a sensitive and reproducible multiplex PCR test enabling simultaneous amplification of the deleted and wild-type NEMO genes in IP female individuals.<sup>24</sup>

A retrospective study on 47 children with IP with the aim to analyze the distribution of manifestations in a pediatric cohort and define guidelines for follow-up of incontinentia pigmenti (IP) was carried out. It was reported that Clinical diagnosis is the first main step for a correct phenotype/genotype correlation, which remains indispensable to better understand the pathological mechanisms of IP and develop new therapies. In doubtful cases, molecular analysis is helpful but characteristic histological features must be added as major criteria for IP diagnosis. Multidisciplinary follow-up is needed, particularly during the first year of life, to detect possible ophthalmologic and neurological complications. Neuroimaging ought to be performed in the case of abnormal neurological examination results or when vascular retinopathy is detected.<sup>25</sup>

### **Osteopetrosis**

The now commonly accepted name of osteopetrosis was proposed in 1926 by Karschner and means literally 'stony or petrified bones.' The essential feature of the disease is the great increase in thickness and density of the cortical and spongy portions of the skeleton and a variable degree of decrease in the space occupied by the bone marrow. Most authors assume that this encroachment of bone on the medullary cavity is responsible for the myelophthisic type of anaemia met with in the severe type of osteopetrosis. The occasional changes in the peripheral blood resembling leukaemia, and the more rare attempts at vicarious haemopoiesis in enlarged liver, spleen and lymph glands are taken to be natural consequences of the same process. It is tempting to explain the anaemia on this simple quantitative basis, but it is equally possible that the changes in the blood-forming elements are primary and that the excessive deposition of bone is a replacement phenomenon.<sup>26</sup>

A six year old boy was reported with hypohidrotic ectodermal dysplasia, immunodeficiency, osteopetrosis and

lymphoedema, associated with a novel mutation in the NF- $\kappa$ B essential modulator (NEMO) gene.<sup>27</sup>

**CONCLUSION**

NF-KB is a protein complex encoded by IKBKG gene. NEMO is responsible for the activation of NF-KB that regulates immune responses and inflammatory reactions. Mutations in NEMO therefore cripple the immune system of children and cause disorders like ectodermal dysplasia's, incontinentia pigmenti and osteopetrosis. These disorders mainly affect the ectodermal development except for osteopetrosis that illustrates predominance in bones. The understanding of the genetic basis of these disorders has aided in the development of new approaches to their diagnosis and treatment.

Table I: LIST OF COMMONLY AFFECTED AREAS IN INCONTINENTIA PIGMENTI

S.No	Area affected	% of people affected
1.	Skin	100
2.	Teeth	90
3.	Bones	40
4.	Brain and Spinal Cord	40
5.	Eyes	35

Table II: EXISTING METHODS OF DIFFERENTIAL DIAGNOSIS FOR INCONTINENTIA PIGMENT

S.No.	Stage of IP	Differential diagnosis
1.	First	Infectious: bullous impetigo, herpes simplex, langerhans cell histiocytosis. Immune mediated: Dermatitis herpetiformis, epidermolysis bullosa acquisita, bullous systemic lupus erythematosus, linear Ig A bullous dermatosis, bullous pemphigoid, pemphigus vulgaris, heritable epidermolysis bullosa, bullous mastocytosis
2.	Second	Verrucae vulgaris, linear epidermal nevi
3.	Third	Linear and whorled nevoid hypomelanosis, dermatopathia pigmentosa reticulosa, Naegeli-Franchosett-Jadessoohn syndrome, X-linked dominant chondrodysplasia punctata, pigment mosaicism.
4.	Various	Goltz syndrome

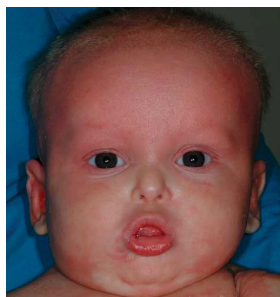


Figure I. Frontal bossing (periorbital wrinkling, and a thickened lower lip)

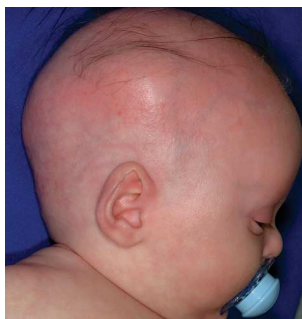

Figure II. Diffuse alopecia, erythema and scaling of scalp

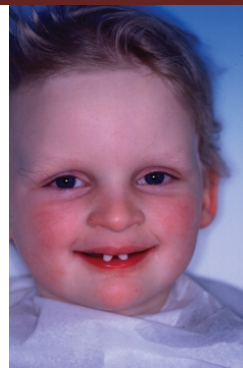

Figure III. Patient at the age of 3 years. The phenotype of ED included a severe hypodontia in both the mandible and the maxilla



Figure IV. Patient with implant.

**REFERENCES**

- Aradhya S, Woffendin H, Jakins T, Bardaro T, Esposito T, Smahi A, Shaw C, Levy M, Munnich A, D'Urso M, Lewis RA, Kenwrick S, Nelson DL. A recurrent deletion in the ubiquitously expressed NEMO (IKK-gamma) gene accounts for the vast majority of incontinentia pigmenti mutations. Hum Mol Gen 2001; 10(19):2171-2179
- Berlin AL, Paller AS, Chan LS. Incontinentia pigmenti: A review and update on the molecular basis of pathophysiology. J Am Acad Dermatol 2002; 47(2):169-187
- Bruckner AL. Incontinentia pigmenti: a window to the role of NF-kappaB function. J Cutan Pathol 2004; 23(2):116-124
- Lee J, Burckart GJ. Nuclear factor kappa B: Important transcription factor and therapeutic target. J Clin Pharmacol 1998; 19: 80-88
- Döffinger R, Smahi A, Bessia C, Geissmann F, Feinberg J, Durandy A, Bodemer C, Kenwrick S, Dupuis-Girod S, Blanche S, Wood P, Rabia SH, Headon DJ, Overbeek PA, Le Deist F, Holland SM, Belani K, Kumararatne DS, Fischer A, Shapiro R, Conley ME, Reimund E, Kalhoff H, Abinun M, Munnich A, Israël A, Courtois G, Casanova JL. X-linked anhidrotic ectodermal dysplasia with immunodeficiency is caused by impaired NF-kappaB signaling. Nature Genet 2001; 27(3):277-285
- Pinheiro M, Freire-Maia N. Ectodermal dysplasias: a clinical classification and a causal review. A J Med Genet 1994; 53: 153-162
- Sofaer JA. A dental approach to carrier screening in X-linked hypohidrotic ectodermal dysplasia. J Med Genet 1981; 18: 459-460
- Pinheiro M, Freire-Maia N. Ectodermal dysplasias: some recollections and classifications. Birth defects 1988; 24: 3-14
- Clarke A, Burn J. Sweat testing to identify female carriers of X-linked hypohidrotic ectodermal dysplasia. J Med Genet 1991; 28: 330-333
- The 30<sup>th</sup> Annual National Foundation for Ectodermal Dysplasias National Family Conference, 2011 Jul 21-3, Hilton Garden Inn, O'Fallon, Illinois. <http://nfededucator.files.wordpress.com/2011/05/11-family-conference-registration.pdf>, date accessed 2011 Dec 25
- Mancini AJ, Lawley L, Uzel G. X-Linked Ectodermal Dysplasia With Immunodeficiency Caused by NEMO Mutation: early recognition and diagnosis. Arch Dermatol 2008(3): 342-6
- Kramer FJ, Baethge C, Tschernitschek H. Implants in children with ectodermal dysplasia: a case report and literature review. Clin Oral Implants Res 2007; 18: 140-146
- Fusco F, Bardaro T, Fimiani G, Mercadante V, Miano MG, Falco G, Israel A, Courtois G, D'Urso M, Ursini MV. Molecular analysis of the genetic defect in a large cohort of IP patients and identification of novel NEMO mutations interfering with NF-kappaB activation. Hum Mol Genet 2004; 13(16):1763-73.

14. Smahi A, Courtois G, Vabres P, Yamaoka S, Heuertz S, Munnich A, et al. Genomic rearrangement in NEMO impairs NF- $\kappa$ B activation and is a cause of incontinentia pigmenti. *Nature* 2000; 405:466-72.
15. Parish L.C, Brenner S, Atlas of Womens dermatology: from infancy to maturity 2011, 88-92
16. Rook/Wilkinson/Ebling , Textbook of dermatology, Oxford Blackwell Scientific publications, 5<sup>th</sup> edition 1992, 1580-1582
17. Ezughah F, Heagerty A, Incontinentia Pigmenti. Midlands dermatology society autumn meeting, Solihull Hospital, 2001 Nov, Book of abstracts.
18. Dahl AA, Incontinentia pigmenti, [http://www.emedicinehealth.com/incontinentia\\_pigmenti/article\\_em.htm](http://www.emedicinehealth.com/incontinentia_pigmenti/article_em.htm), date accessed 2011 Dec 30
19. Definition of Syndrome, Bloch-Sulzberger, Medterms medical dictionary, <http://www.medterms.com/script/main/art.asp?articlekey=5619>, date accessed 2012 Jan 12
20. Wammanda RD, Idris HW, Musa S, Chom ND, Akuyam SA. Incontinentia pigmenti associated with precocious puberty: Case report. *Annals of African Medicine*, 2006; 5(2): 111-113
21. Morton GF. Macular vasculopathy and its evolution in incontinentia pigmenti. *Trans Am Ophthalmol Soc* 1998, 96: 55-65
22. Kane KM, Ryder JB, Johnson RA, Baden HP, Stratigos A. Color atlas and synopsis of pediatric dermatology, 292-295
23. Thakur S, Puri RD, Kohli S, Saxena R, Verma IC. Utility of molecular studies in incontinentia pigmenti patients, *Indian J Med Res* 2011; 133: 442-445
24. Steffann J, Valérie R, Smahi A, Woffendin H, Munnich A, Kenwrick SJ, Grebille AG, Benachi A, Dumez Y, Bonnefont JP, Rabia SH. A novel approach for prenatal detection of the common NEMO rearrangement in incontinentia pigmenti. *Prenatal diagnosis* 2004; 24(5): 384-388
25. Rabia SH, Froidevaux D, Bodak N, Dominique HT, Smahi A, Yasmina T, Fraitag S, Prost Y, Bodemer C. Clinical study of 40 cases of incontinentia pigmenti. *Arch Dermatol* 2003; 139: 1163-1170
26. Nussey AM. Osteopetrosis. *Arch Dis Child* 1938; 13: 161-172
27. Roberts CM, Angus JE, Leach IH, McDermott EM, Walker DA, Ravenscroft JC. A novel NEMO gene mutation causing osteopetrosis, lymphoedema, hypohidrotic ectodermal dysplasia and immunodeficiency (OL-HED-ID). *Eur J Pediatr* 2010 ; 169 (11): 1403-1407

Source of support: Nil, Conflict of interest: None Declared