



## COMPARISON BETWEEN THE EFFECT OF AQUEOUS AND METHANOLIC EXTRACTS OF HOLARRHENA ANTIDYSENTERICA BARK AGAINST EXPERIMENTALLY INDUCED INFLAMMATORY BOWEL DISEASE

Darji Vinay C.<sup>1\*</sup>, Deshpande Shrikalp S.<sup>2</sup>, Bariya Aditi H.<sup>3</sup>

<sup>1</sup>Department of Pharmacology, Sharda School of Pharmacy, Pethapur-Mahudi road, Pethapur, Gandhinagar, Gujarat, India

<sup>2</sup>Department of Pharmacology, K.B. Institute of Pharmaceutical Education & Research, Sector-23, Gandhinagar, Gujarat, India

<sup>3</sup>Department of Pharmacology, Kalol Institute of Pharmacy, Kalol, Gandhinagar, Gujarat, India

Article Received on: 13/11/12 Revised on: 01/12/12 Approved for publication: 31/12/12

\*E-mail: vinay\_pharma05@yahoo.com

### ABSTRACT

It has been demonstrated that *Holarrhena antidysenterica* Wall. (*Apocynaceae*) is useful as an adjunctive therapy for Inflammatory bowel disease (IBD). However, its effect on ulcerative colitis has not been investigated. In the present study, aqueous and methanolic extracts of *Holarrhena antidysenterica* were tested for 2, 4 - dinitro benzene sulfonic acid (DNBS) induced colitis, and antioxidant activity were evaluated to clarify possible mode of action. Male albino wistar rats were randomly divided into six groups: Normal control (Group I), Vehical contol (Group II), colitis induced by DNBS without any therapy (Group III), colitis treated with standard Dexamethasone (Group IV), colitis treated with methanolic extract of test drug *Holarrhena antidysenterica* (Group V), colitis treated with aqueous extract of test drug *Holarrhena antidysenterica* (Group VI). Treatment was given for 18 days. Rats were sacrificed on the 18<sup>th</sup> day after the procedure and the levels of Malondialdehyde (MDA), Nitric oxide (NO), Reduced glutathione (GSH), Superoxide dismutase (SOD) were measured in the isolated colon tissue. MDA & NO levels in colon tissue homogenate were decreased while SOD & GSH level were increased in group IV, V & VI as compared to those of Group III. There was also increase in food intake, water intake & decreased colon weight in Group IV, V & VI as compared to Group III. There was also improvement in inflammatory indices of colon mucosal damage index (CMDI) & disease activity index (DAI) & histopathology of Group IV, V & VI as compared to those of group III. Levels of all the chemical parameters, Physical parameters & Histological parameters were significantly improved after the treatment with methanolic extract of test drug compared to aqueous extract of test drug. Treatment with aqueous extract also improves the colitis condition but it was not significantly improved by it as compared to methanolic extract of test drug. The results of our study suggest that therapy with methanolic extract of *Holarrhena antidysenterica* has beneficial effects on the course of experimental colitis compared to aqueous extract of *Holarrhena antidysenterica*.

**Keywords:** *Holarrhena antidysenterica* Wall (*Apocynaceae*), Inflammatory bowel disease (IBD), Colitis

### INTRODUCTION

IBD is a chronic inflammatory disease of gastrointestinal tract. It comprises the two conditions, Crohn's disease and ulcerative colitis, characterized by chronic recurrent ulceration of the bowel. Although the exact etiopathogenesis of IBD is still not clear, it appears that there is chronic activation of the immunoinflammatory cascade with transient tethering of leukocytes to the endothelium<sup>1</sup>. This inflammatory response is most likely made possible by defects in both the mucosal immune system and the barrier function of the intestinal epithelium. Sequence of events involving control of infection, resolution of inflammation, differentiation & remodeling are the key processes for the treatment of IBD.

Conventional drugs for colitis treatment include aminosalicylate, corticosteroids, antibiotics & immunomodulators. 5- Amino salicylic acid having side effects in 30% of the patients. Systemic corticosteroids producing incidence of complication is 4.3%. Antibiotic therapy is beneficial in 70% of the patients & immunomodulators having 50 to 70% beneficial effects<sup>2</sup>. This report shows that there is no any appropriate treatment available to treat IBD without side effects. So we are searching for a herbal remedy which will show beneficial effects without side effects in experimentally induced colitis in rats.

*Holarrhena antidysenterica* is a reputed plant in ayurvedic system of medicine; it has Antioxidant<sup>3</sup>, antiameobic<sup>4</sup>, antibacterial & anti diarrhoeal<sup>5</sup> activity. In the light of this the present investigation was undertaken to study the potential of *Holarrhena antidysenterica* in the treatment of inflammatory bowel disease using DNBS induced colitis in rat. Main constituents present in *Holarrhena antidysenterica* are

alkaloids which are responsible for their various activities. Alkaloids are generally water insoluble in nature but *Holarrhena antidysenterica* plant consist of the conessine alkaloid which is water soluble in nature and also responsible for the various pharmacological activities. Others alkaloids which are present in plant is non-polar in nature and they also possess the various pharmacological actions. Therefore in this study we evaluated both Aqueous as well as methanolic extract of *Holarrhena antidysenteric* plant against DNBS induced IBD.

### MATERIALS AND METHODS:

#### Plant material:

*Holarrhena antidysenterica* Wall. (Syn: Kurchi, Family: Apocynaceae) bark sample was collected from commercial supplier (LVG) of Ahmedabad. Bark sample of *Holarrhena antidysenterica* was identified and authenticated by Mr. K.M. Chavda, Lecturer, Department of Biology, Seth L.H. Science College, Mansa, Gujarat, India.

#### Preparation of extract:

Sufficient quantity of Bark sample of *Holarrhena antidysenterica* was crushed and powdered. After that dried powder (250 gm) of bark was extracted with methanol (70%) using Soxhlet apparatus. After completion of Extraction process, pooled extract was concentrated to dryness to get a solid mass (Percentage Yield Value: 1.8 %). Aqueous extract was also prepared using Soxhlet apparatus (Percentage Yield Value: 1.4 %).

#### Animals:

Male albino wistar rats weighing 250-300 gm were housed in metabolic cages with free access to standard rat chow (diet) and water ad libitum for one week before the experiment. The experimental protocol was approved by Institutional Animal

Ethical Committee as per the guidance of committee for the purpose of Control and Supervision of Experiments on Animals (CPCSEA), Ministry of Social Justice and Empowerment, Government of India.

Animals were divided into 6 different groups with 6 animals in each group. Study period for all these groups was 18 days. Group I served as a normal control & received the standard diet throughout the experimental period. Group II served as vehicle control group & received 1.6 ml/kg of 50% ethanol intrarectally. Experimental colitis was induced by 2, 4 - dinitro benzene sulfonic acid (DNBS).<sup>6</sup> Group III, IV, V and VI were received the DNBS 120 mg/kg intrarectally on 1<sup>st</sup> day. Group III served as model control group. After the induction of IBD, from the 4<sup>th</sup> day Group IV, V and VI were received Standard- Dexamethasone 2 mg/kg, i.p., methanolic extract of bark sample of *Holarrhena antidysenterica* 400 mg/kg, p.o and aqueous extract of bark sample of *Holarrhena antidysenterica* 400 mg/kg, p.o. respectively for throughout study period of 15 days.

**Evaluation of physical, histological and biochemical parameters:**

During study total water intake, food intake of each group was measured daily. Animals were sacrificed at the end of study period, colon segment was taken from 10 cm proximal to anus, weighed and scored for inflammatory indices, using the scoring formula of colon mucosa damage index (CMDI) & disease activity index (DAI).<sup>7</sup> Colon samples collected at the end of the study were homogenized & centrifuged to get supernatant which was used to assay Malondialdehyde (MDA)<sup>8</sup>, Nitric oxide (NO)<sup>9</sup>, Reduced glutathione (GSH)<sup>10</sup>, Superoxide dismutase (SOD).<sup>11</sup>

**Histopathology:**

Sample of colon from one animal of group I, III, IV, V & VI was collected at the end of study for histopathological evaluation. Photomicrograph of the haematoxylin and eosin stained section of rat colon were taken.

**Statistics**

All results were expressed as mean ± S.E.M. p<0.05 was considered statistically significant. Statistical difference between the means of the various groups were analyzed using one-way analysis of variance.

**Table 1. Effect of *Holarrhena antidysenterica* on physical & histological parameters**

Group	Histological parameters(n=6)		Physical parameters(n=6)		
	CMDI (Grade)	DAI (Grade)	Water intake ml/day/gp	Food intake gm/day/gp	Colon weight mg/rat
Normal control	0.17± 0.17	0.17± 0.16	169.44± 2.78	132.22± 1.91	1749.17± 44.64
Vehicle control	0.67± 0.21	0.5± 0.20	164.17± 2.51	130.56± 2.057	1779.17± 39
Model control	3.3± 0.21*	3.5± 0.22*	110± 5.77*	55± 10.41*	2435.83± 53.4*
Std	1.5± 0.22#	1.00± 0.26#	142.78± 6.17##	107.22± 6.83##	1959.5± 47.46#
Methanolic extract	1.67± 0.21#	1.5± 0.22#	139.17± 7.21	104.44± 6.25##	2017.83± 47.66#
Aqueous extract	2.33± 0.21	2.33± 0.21	137.06± 5.97	94.17± 5.10##	2121.67± 68.33##

Values are expressed as mean ± S.E.M.

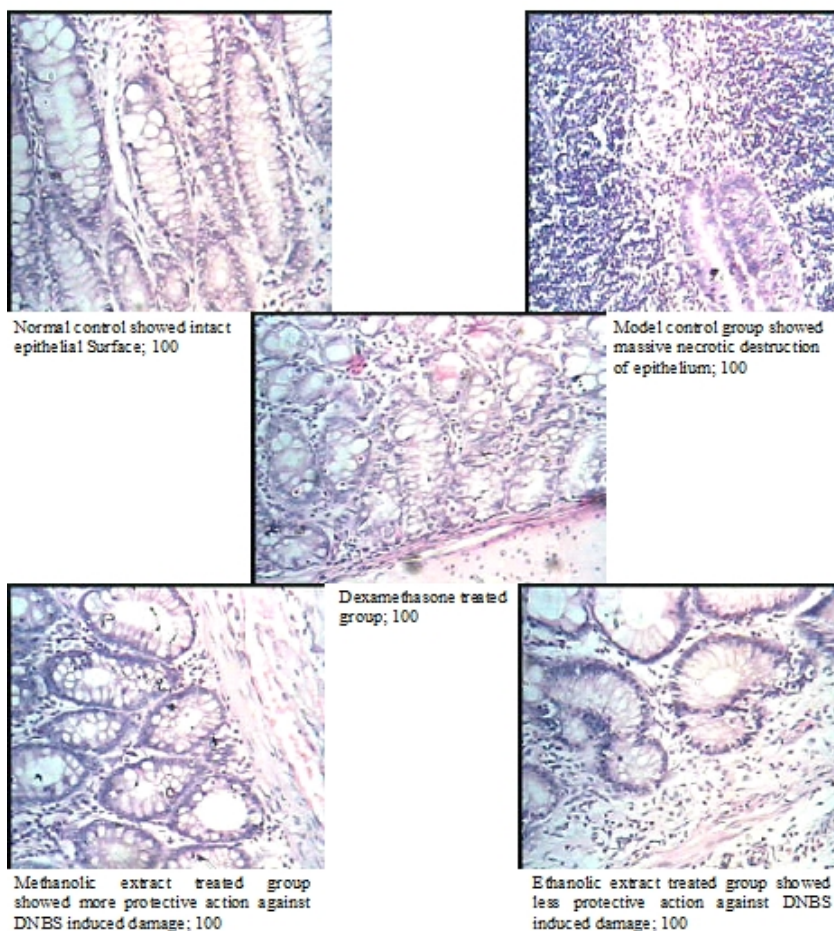
\* Significantly different from Normal control group at p < 0.001, \*\*Significantly different from Normal control group at p < 0.05, # Significantly different from DNBS control group at p < 0.001, ##significantly different from DNBS control group at p < 0.05

**Table 2. Effect of *Holarrhena antidysenterica* on biochemical parameters.**

Group	Biochemical (n=6)			
	MDA µg/ml	NO µmoles/ml	GSH µg/ml	SOD U/gm of tissue
Normal control	0.19±0.04	419.37±84.17	298.75±29.47	13.46±2.91
Vehicle control	0.19±0.02	467.81±101.9	288.25±26.22	13.34±2.26
Model control	2.0±0.35*	1328.21±96.97*	104.67±18.53*	3.89±1.66**
Standard	0.32±0.04#	624.5±100.8#	237.5±22.32#	12.23±1.84##
Methanolic extract	0.36±0.05#	558.97±108.4#	204.83±25.88##	9.81±1.92##
Aqueous extract	1.090±0.4	977.77 ±124##	147.5± 21.41	7.55±1.45

Values are expressed as mean ± S.E.M.

\* Significantly different from Normal control group at p < 0.001, \*\*Significantly different from Normal control group at p < 0.05, # Significantly different from DNBS control group at p < 0.001, ##significantly different from DNBS control group at p < 0.05

**Figure 1: Histopathology of Isolated Colon:****RESULTS & DISCUSSION:**

Of the several animal models of intestinal inflammation, the well-characterized haptene reagent 2,4 dinitrobenzene sulphonic acid (DNBS)-induced colitis resembles human IBD in terms of its various histological features including infiltration of colonic mucosa by neutrophils and macrophages and increased production of inflammatory mediators including T helper 1 profile of cytokines<sup>12</sup>. Therefore in the present study DNBS was used for induction of colitis in the rats to determine the effect of *Holarrhena antidysenterica* on inflammatory bowel disease. DNBS caused mucosal damage, as evident by the increase in CMDI & DAI score as compared to normal control. This increase in CMDI and DAI score was significantly reversed on treatment with methanolic extract of *Holarrhena antidysenterica* compared to aqueous extract of the plant (Table 1). Induction of inflammatory bowel disease by DNBS was further supported by decrease in water intake, food intake & increased Colon weight in the model control group animals as compared to the normal control group animals. Both the extract of *Holarrhena antidysenterica* showed improvement in above physical parameters as compared to the model control group (Table 1). Vehicle control group showed no significant change in histological as well as physical parameters as compared to the normal control group animals. DNBS model of IBD has been found to be associated with an overproduction of nitric oxide (NO) because of the

expression of the inducible isoform of NO synthase (iNOS)<sup>13</sup>. In an inflammatory focus, NO may react with superoxide anion, resulting in oxidative tissue damage through production of peroxynitrite, which is believed to mediate many of the destructive effects of NO in colon inflammation<sup>14</sup>. Thus NO is responsible for oxidative stress which is associated with increased levels of MPO which catalyses the conversion of proportionally more stable hydrogen peroxide to unstable hydrochloric acid. Additionally MPO induces neutrophil infiltration on mucosal area causing further damage to the tissue<sup>15</sup>. Malondialdehyde is final product of oxidative stress and is good indicator for extent of oxidative stress<sup>16</sup>. Preventive anti-oxidant, such as superoxide dismutase (SOD) enzyme is the first line of defense against reactive oxygen species<sup>17</sup>. Superoxide dismutase (SOD) is widely distributed in cells with high oxidative metabolism and has been proposed to protect such cells against the deleterious effect of superoxide anion<sup>18</sup>. Reduced glutathione (GSH) is a major low molecular weight scavenger of free radicals in the cytoplasm and an important inhibitor of free radical mediated lipid peroxidation. During oxidative stress, GSH gets oxidized and cannot be regenerated.<sup>19</sup>

In the present study DNBS model control group showed elevated levels of NO, MDA and decreased levels of SOD & GSH as compared to normal control group animals, suggesting the possible role of oxidative stress in the

induction of colitis. Treatment with methanolic and aqueous of *Holarrhena antidysenterica* decreased the NO level (Table 2) thus suggesting that reduction in iNOS generation may be among the mechanisms responsible for the anti-inflammatory effect of it. Effect of methanolic extract was more on the NO level compared to aqueous extract of plant. Further more treatment with methanolic extract of plant also prevents to increase levels of MDA compared to treatment with aqueous extract (Table 2). Anti oxidant defenses were strengthened by treatment with methanolic extract of *Holarrhena antidysenterica* as revealed by increase in SOD & GSH levels as compared to the model control group animals. Aqueous extract also improves the level of all chemical parameters but it was significantly improved by it as compared to methanolic extract of plant (Table 2).

The most important microscopic findings in human inflammatory bowel disease are the loss of mucus<sup>20</sup>, crypt abscess<sup>21</sup> and glandular distortion<sup>22</sup>. Photomicrograph of the haematoxylin and eosin stained section of rat colon showed that DNBS significantly affect the cell structure of the colon. There was rupture of Goblet cells, inflammatory damages to the mucosal layers & inflammatory cellular infiltration observed in the colon of DNBS control animals as compared to normal control group animals. These changes were significantly prevented by standard as well as methanolic extract of the test drug *Holarrhena antidysenterica* (Figure 1).

#### CONCLUSION:

The present study proved the potential effect of methanolic extract of *Holarrhena antidysenterica* bark in inflammatory bowel disease compared to the aqueous extract of *Holarrhena antidysenterica* bark. It may be due to its antioxidant & anti inflammatory activity.

#### ACKNOWLEDGEMENT:

Mr. K.M. Chavda, Lecturer, Department of Biology, Seth L.H. Science College, Mansa, Gujarat, India for authentication of Bark sample of *Holarrhena antidysenterica*. Suvik pharmaceuticals Ltd. for providing gift sample of Dexamethasone standard drug.

#### REFERENCES:

- Deniel K, Podolsky M.D. Inflammatory bowel disease, *New England journal of medicines*, Aug 8, 2002, vol 347, No. 6.
- V. alin botoman, M.D, Gregory F. Bonner, M.D. Cleveland Clinic Florida, Ft. Lauderdale, Florida, Daniela A. Botoman, M.D.. North Broward Hospital District Family Practice Program of the University of South Florida, Coral Springs, Florida, *American family physician*, January 1, 1998. Vol. 57, No. 1.
- Rahman Shafiq, Ali Eunos, Haque Rubyat. Pharmacological profiles of *Holarrhena antidysenterica* (L.) Wall bark, *Oriental pharmacy & Experimental medicine*. 2007; 7(2): 157-161.
- Dutta NK, Iyer SN, Anti-amoebic value of berberine and kurchi alkaloids. *J Indian Med Assoc*. 1968; 50(8): 349-52.
- Kavitha D, Shilpa PN, Devaraj SN. Antibacterial and anti diarrhoeal effects of alkaloids of *Holarrhena antidysenterica* WALL. *Indian J Exp Biol*. 2004; 42(6): 589-94.
- Cuzzocrea S, McDonald M C, Mazzon E. Calpain inhibitor I reduce colon injury caused by dinitrobenzene sulphonic acid in the rat. *Gut* 2001; 48:478-488.
- Wei-Guo, Shao-Ping L, Bao-Ping Y. Ameliorative Effects of sodium ferulate on experimental induced colitis *World Journal of Gastroenterology* 2003;9 2533-2538.
- Ohkawa I, Ohisi N, Yagi K. Assay for lipid peroxides in animal tissue by thiobarbituric acid reaction. *Anal Biochem* 1979; 95:351-358.
- Lisa A, Rindnour, Julia E, Micheal A H et al. A Spectrophotometric method for the direct detection and quantification of nitric oxide, nitrates and nitrite in cell culture media. *Analytical Biochemistry* 2000; 281,223-229.
- Moron MS, Depierre JW, Mannervik B. Levels of glutathione, glutathione reductase and glutathione S transferase activities in rat lung and liver. *Biochem Biophys Acta* 1979; 582: 67-78.
- Misra HP, Fridovich I et al. The role of superoxide anion in the autoxidation of epinephrine and a simple assay for superoxide dismutase. *J Biol Chem* 1972; 247:3170 – 3175.
- Parronchi P., Romagnani P., Annunziato F., Sampugnaro S., Becchio A., Giannarini L., Maggi E., Pupilli C., Tonelli F. & Romagnani S et al. Type 1 helper cell predominance and interleukin-12 expression in the gut of patients with Crohn's disease. *Am. J. Pathol* 1997, 150, 823 – 832.
- Nathan C et al. Nitric oxide as a secretory product of mammalian cells. *fafeb j*, 1996, 3051 – 3064.
- McCafferty DM. Peroxynitrite and inflammatory bowel disease. *Gut* 2000; 46:436–9.
- Sekizuka E, Grisham MB, Li MA, Deitch EA, Granger DN et al. Inflammation-induced intestinal hyperemia in the rat: role of neutrophils. *Gastroenterology*. 1988; 95(6):1528–1534.
- Cheesman, K.H et al. Lipid peroxidation in biological systems. In: Halliwell, B., Aruoma, O.I. (Eds.), *DNA and Free Radicals*. Ellis Horwood, London, 1993 pp. 12–17.
- Halliwell, B., Antioxidant characterization: methodology and mechanism. *Biochem. Pharmacol.* 1995, 49, 1341–1348.
- Fridovich I et al. Superoxide dismutases. *Ann Rev Biochem* 1975; 44:147– 59.
- Halliwell, B., Antioxidant characterization: methodology and mechanism. *Biochem. Pharmacol.* 1995; 49: 1341–8.
- Surawicz cm: Mucosal biopsy diagnosis of colitis. *Semin Colon Rectal Surg* 3: 157-159, 1992.
- Le berre n, heresback o, kerbaol m, kerbaol m, caulet s, bretagne jf, chaperon j, gosselin m, ramee mp: histological discrimination of idiopathic inflammatory bowel disease from other types of colitis. *j clin pathol* 1995;48: 749-753.
- Seldenrijk ca, morson bc, meuwissen sgm, schipper nw, lindermand j, meijer cjm: histopathological evaluation of colonic mucosal biopsy specimens in chronic inflammatory bowel disease; diagnostic implications. *Gut*, 1991, 32: 1514-1520.

Source of support: Nil, Conflict of interest: None Declared