



## Research Article

### HEPATOPROTECTIVE ACTIVITY OF *INULA CAPPA* DC. AQUEOUS EXTRACT AGAINST CARBON TETRACHLORIDE INDUCED HEPATOTOXICITY IN WISTAR RATS

Ajit Kiran Kaur \*, Sokindra Kumar, Pradeep Kumar Sharma  
R.V. Northland Institute, Dadri, Greater Noida, G B Nagar, U.P., India  
\*Corresponding Author Email: kiran\_cognosy@yahoo.com

Article Received on: 25/11/16 Revised on: 23/12/16 Approved for publication: 06/01/17

DOI: 10.7897/2230-8407.08013

#### ABSTRACT

*Inula cappa* is well known for its medicinal properties like anti-inflammatory, digestive, depurative, carminative, analgesics, antipyretics, treatment of peptic ulcer etc. The present study focuses on the ability of *I. cappa* to alleviate liver damage caused by over carbon tetrachloride. The aqueous extract of whole plant of *I. cappa* (400 mg/kg, p.o) significantly showed hepatoprotective activity followed by whole plant extract at dose of 200mg/kg body weight and least hepatoprotective effect was observed with stem extract. Histopathological liver sections also revealed that the normal liver architecture was disturbed by hepatotoxin in carbon tetrachloride group, whereas the liver sections of the rat treated with the aqueous extract showed normal cellular architecture and is comparable with the standard silymarin treated group. Hence the aqueous extract of whole plant confirms hepatoprotective effect in carbon tetrachloride induced hepatotoxicity in rats.

**Keywords:** Hepatoprotective, Aqueous extract, Histopathology, *Inula cappa*

#### INTRODUCTION

The liver is the largest gland of the body playing an astonishing array of vital functions in the continuation, performance and adaptable homeostasis of the body. It is concerned with approximately all the biochemical pathway to enlargement, fight in opposition to disease, nutrient contribute, energy stipulation and reproduction<sup>1</sup>. Liver disease is one of the major causes of morbidity and mortality in public which affects humans of all ages. Due to liver disease about 20,000 deaths occur every year<sup>2</sup>. Some of the commonly known disorders of liver are viral hepatitis, alcohol liver disease, non-alcoholic fatty liver disease, autoimmune liver disease, metabolic liver disease, drug induced liver injury, gallstones etc. Hepatocellular carcinoma is one of the ten most common tumours in the world with over 2, 50,000 new cases each year<sup>2</sup>. Cell damage is caused by free radicals through mechanisms of covalent binding and lipid peroxidation with subsequent tissue injury. Some synthetic compounds are currently available as hepatoprotective agents. However, such compounds may exert several side effect and disadvantages. In view of severe adverse side effects of synthetic agents, there is growing focus to develop more valuable and protected drugs which may raise the therapeutic benefits for patients<sup>3</sup>. Numerous medicinal plants and their formulations are used for liver disorders in ethnomedical practices as well as in traditional systems of medicine in India<sup>4</sup>.

*Inula cappa* DC is an erect deciduous or subdeciduous shrub also known as Athhu and Tamagari<sup>5</sup> is 1-3 feet high with sparingly branched or unbranched stems up to 0.5 inch in diameter, the shoots often dying back almost to the ground each year, though usually a portion persists. *Inula* species has been used in folk medicine as tonic, diuretic, stomachic, diaphoretic, anti-inflammatory, bactericidal, hepatoprotective, anti-tumour and carminative<sup>6</sup>. The chemical constituents sesquiterpenoid,

triterpenoids, steroids, anthraquinones, flavonoids, balmy compounds, amides, organic acids have been reported from the roots of *Inula cappa*, and the triterpenoids and steroids were the most predominant constituents. Twenty compounds were isolated from the flowers of *Inula cappa*, and nine compounds were identified based on chemical and spectral analysis including one sesquiterpenoid, two triterpenoids, one steroid, one lignanoid, one aromatic compound and three flavonoids<sup>7</sup>. Thirty-one compounds were isolated from the ethanolic extract of the whole herb<sup>8</sup>. Bark is found to contain lignoceric acid, oleic acid, stearic acid, palmitic acid, myristic acid, lauric acid, capric acid, caprylic acid<sup>9</sup>. The information about *Inula* species prompted us to study the hepatoprotective activity of *Inula cappa*.

#### MATERIALS AND METHODS

##### Chemicals

All chemicals and solvents used in the study were of analytical grade. The chemicals were obtained from Qualigens fine chemicals and Fisher Scientific. Arba kit and Auto pak kit were obtained from Trans Asia bio medical Ltd, Mumbai and Siemens health care diagnostic company, Baroda.

##### Plant material and preparation of the extract

The plant *Inula cappa* was collected from Nainital in the month of December-2011. The plant was identified and authenticated by Dr.V.Singh, Emeritus Professor, Department of Botany, C.C.S. University, Meerut, India. The coarsely powdered leaf, stem and whole plant (root, stem, flower, leaf) of *Inula cappa* was decocted in purified boiling water in the ratio of 1:9 for 30 mins. Decoction was kept overnight and filtered as per

procedure adopted by M. Anusha et al.<sup>10</sup>. The aqueous extract was filtered through a cotton plug, followed by Whatman filter paper no.1 and then concentrated by using a rotary evaporator at a low temperature (40-60°C) and reduced pressure.

### Preliminary phytochemical analysis

The aqueous extracts (leaf, stem and whole plant) were then subjected to preliminary phytochemical<sup>11</sup> analysis to assess the presence of various phytoconstituents. This revealed the presence of flavonoids, sesquiterpene lactones, carbohydrates, phenolic compounds and glycosides. These preliminary phytochemical tests are mentioned in Table 1.

### Animals

Wistar albino rats weighing 180-250g of either sex maintained under standard husbandry conditions (temp 23±2°C, relative humidity 55±10% and 12 hours' light dark cycle) were used for the screening. Animals were fed with standard laboratory food and ad libitum during the study period. The experiments were performed after the experimental protocols approved by the institutional animal ethical committee, India 2009. The ethical clearance number is 1149/PO/Ere/S/07/CPCSEA.

### Acute toxicity studies

Acute oral toxicity study was performed as per OECD-423 guidelines<sup>12</sup>. The drugs were administered orally in doses of 5, 50, 300, 2000 mg/kg bodyweight to groups of rats (n = 3) and the percentage mortality was recorded over a period of 24 hour. During the first 1 hour of drug administration, rats were observed for gross behavioral changes as described by Irwin et al.<sup>13</sup>. If mortality was observed in two animals out of three animals, then the dose administered was assigned as toxic dose. If the mortality was observed in one animal, then the same dose was repeated to confirm the toxic dose. As mortality was not observed, the procedure was repeated for further higher doses such as 50, 300 and 2000mg/kg body weight. The animals were observed for toxic symptoms for 72 hour as per procedure adopted by Rekha Rajendran<sup>14</sup>.

### Carbon tetrachloride induced hepatotoxicity

The animals were divided into nine groups of six animals each and labelled (Groups F1 to F9). Group I (F1) served as normal control and received sterile olive oil (vehicle) 1ml/kg (p.o). Group II (F2) animals constituted the hepatotoxic group, and received CCl<sub>4</sub> suspended in sterile olive oil (1:1 v/v, 2 ml/kg, i.p.) every 72 h for 10 days. Group III (F3) received standard drug silymarin 100 mg/kg (p.o) for 10 days and CCl<sub>4</sub> suspended in sterile olive oil (1:1 v/v, 2 ml/kg, ip). Groups IV - IX (F4 - F9) received aqueous extract (200 and 400 mg/kg/day) of stem, leaf and complete plant suspended in 0.5 % sodium carboxymethylcellulose for 10 days and CCl<sub>4</sub> suspended in sterile olive oil (1:1 v/v, 2 ml/kg, ip). At the end of the experimental period, the rats were fasted overnight and sacrificed by ether anesthesia. Blood and liver samples were collected for biochemical and histological studies<sup>15</sup>.

### Assessment of liver function

Blood was collected from all the groups by puncturing the retro-orbital plexus and could clot at room temperature and serum was separated by centrifugation at 2500 rpm for 10 min. The serum was used for estimation of biochemical parameters to determine the functional state of the liver<sup>14,15</sup>. Serum glutamic oxaloacetic

transaminase (SGOT), serum glutamic pyruvic transaminase (SGPT), alkaline phosphatase (ALP), Total bilirubin (TB) and Direct bilirubin (DL) were estimated<sup>16</sup> by Arba kit (Trans Asia bio medical Ltd. Mumbai) and Autopak kit (Siemens health care diagnostic company, Baroda).

### Histopathological studies

The animals were sacrificed and the abdomen was cut open to remove the liver. Paraffin sections (7 µm thick) of buffered formalin-fixed liver samples were stained with hematoxylin-eosin (which stains the nuclei blue and the cytoplasm pink) to study the liver histological structure of the control and treated rats. The sections were then observed under microscope for histopathological changes in liver architecture and their photomicrographs were taken<sup>14,15</sup>.

### Statistical analysis

For determination of significant inter-group differences, each parameter was analyzed separately by 't' test and one way analysis of variance. Dunnet's test was used for individual comparisons. The p < 0.05 was considered as statistical significant.

## RESULT

### Acute toxicity studies

Aqueous extracts of *Inula cappa* did not produce any toxic symptoms or mortality up to the dose level of 2000mg/kg body weight in rats, hence the extract was safe and non-toxic for further pharmacological screening.

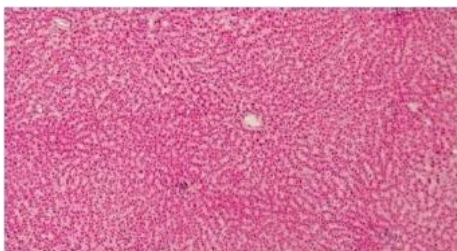
### Hepatoprotective activity

Hepatoprotective effects of leaf, whole plant and stem extracts at high dose and low dose were studied. Various determinants of liver injury, such as Serum glutamate oxaloacetate transferase (SGOT), Serum glutamate pyruvate transaminase (SGPT), alkaline phosphatase (ALP), total bilirubin (TB) and direct bilirubin (DB) were evaluated. It was observed that SGOT, SGPT, TB and DB were found to be elevated in CCl<sub>4</sub> group as CCl<sub>4</sub> causes severe liver injury leading to elevated enzyme level and increased bilirubin levels. In the present study, the values of SGPT were 39.44±0.90 in normal rats which was significantly raised to 648.06±8.39 in CCl<sub>4</sub> treated rats and its level was significantly restored by high dose (400mg/kg) of whole plant extract to 281.43±5.28 followed by low dose (200mg/kg) of whole plant extract restoring the level up to 313.75±5.36. The level of SGPT restoration by leaf and stem extract of *Inula cappa* was less as compared to whole plant extract at both the doses. Similarly, the level of SGOT in normal rats was 48.28±1.32 which increased in CCl<sub>4</sub> treated rats up to 666.81±7.48 and it is restored to normal 283.63±6.03 by high dose of whole plant aqueous extract (WPAE) of *Inula cappa* when compared to silymarin treated group. The restoration SGOT values were less in leaf aqueous extract (LAE) treated groups and stem aqueous extract (SAE) treated groups. Similarly, the level of alkaline phosphatase (ALP) in normal rats was 733.89±5.72 was raised in CCl<sub>4</sub> intoxicated rats up to 666.81±7.48 and was restored to normal by high dose of WPAE of *Inula cappa*. The level of alkaline phosphatase was also restored by LAE and SAE of *Inula cappa* but that was less significant as compared to WPAE. (Table 2, Figure 1, 2).

**Effect of silymarin and extracts pre-treatment on pathological histology of rat livers after CCL<sub>4</sub> induced acute toxicity**

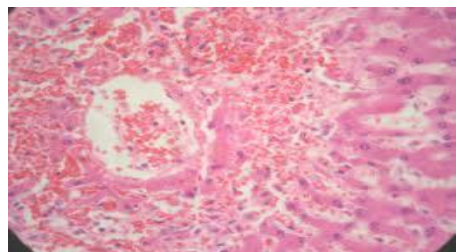
Histopathological studies of the liver section of rats were carried out to confirm the serum analysis results and hepatoprotective effect of the treatments. Histopathological observations supported the results obtained from serum enzyme assays. The CCL<sub>4</sub> induced histopathological changes in liver were confirmed. Silymarin and extracts pre-treatment reversed the effect of CCL<sub>4</sub>. Figure shows that CCL<sub>4</sub> induced liver injury caused significant fatty degeneration of hepatic cells, vacuole formation in the central vein, hepatocyte ballooning and inflammation after CCL<sub>4</sub> treatment. Treatment with silymarin and extracts reduced the injury level, vacuole formation and inflammation and showed a preventive effect against CCL<sub>4</sub> induced acute hepatotoxicity.

The histopathological findings of rat livers pre-treated with silymarin and extracts were as follows-



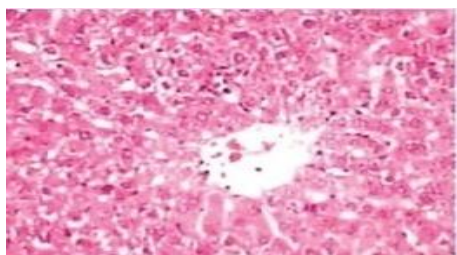
**Group-I**

In case of Normal Control (Group-I) group hepatic globular structure; central veins, portal tracts, hepatocytes and sinusoids appeared normal; the lobular unit was also well identified.



**Group-II**

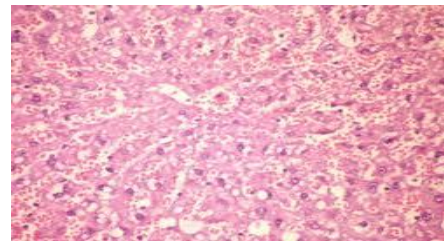
In case of CCL<sub>4</sub> treated group (Group-II), liver section showed the damage of the liver cells, with ballooning of hepatocytes, patchy parenchymal necrosis along with marked fatty and proteinaceous degeneration and lobular inflammation; sinusoidal spaces were flooded with inflammatory cells.



**Group-III**

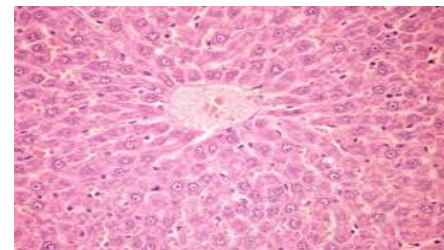
Liver section of silymarin (100 mg/kg) pre-treated group (Group-III) showed normal architecture with very mild degree

of proteinaceous degeneration, slight periportal mono-nuclear infiltration with patchy necrosis of hepatocyte was also observed.



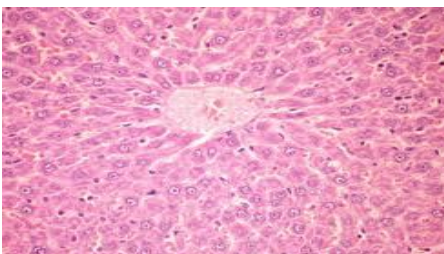
**Group-IV**

In case of stem extract (200 mg/kg) treated group (Group-IV) showed normal architecture of hepatocytes with accumulation of fatty vacuoles and proteinaceous degeneration with periportal mono-nuclear infiltration and patchy necrosis.



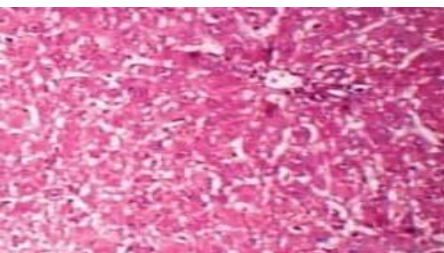
**Group-V**

The histology of liver section of rat pretreated with stem extract (400 mg/kg) (Group-V) appears normal with central vein, portal triads and architecture.



**Group-VI**

The section of liver of rat pretreated with leaf extract (200 mg/kg) treated group (Group-VI); section of liver showed normal hepatocyte, with mild inflammation in portal tract with patchy necrosis.

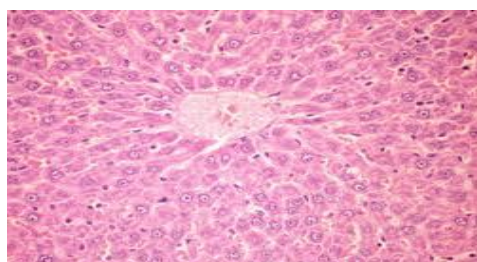


**Group-VII**

The histology of liver section of rat pretreated with leaf extract (400 mg/kg) (Group-VII) appears normal with central vein,

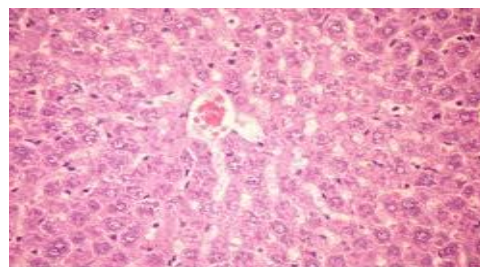


portal triads and architecture. No necrosis was seen with reversal of toxic effects.



**Group-VIII**

Whole plant extract (200 mg/kg) treated group (Group-VIII); section of liver showed normal hepatocyte, with mild inflammation in portal tract.



**Group-IX**

Also, the histology of liver section of rat pretreated with whole plant extract (400 mg/kg) (Group-IX) appears with normal central vein, portal triads and architecture. No necrosis was seen and some of the hepatocytes showed regenerative activity with reversal of toxic effects.

**Table 1: Phytochemical screening of *Inula cappa***

S. No	Test	Leaf Et	Leaf Aq	Flower Et	Flower Aq	Root Et	Root Aq	Stem Et	Stem Aq	Whole plant Et	Whole Plant Aq
1	Carbohydrates	+	+	+	+	+	-	+	+	+	+
2	Mucilage	-	-	-	-	+	-	+	+	-	-
3	Proteins	-	-	-	-	-	-	-	-	-	-
4	Amino acids	-	-	-	-	+	-	-	-	-	-
5	Steroids and Triterpenoids	+	+	+	+	-	-	+	+	+	+
6	Glycosides	-	-	-	-	+	+	+	+	+	+
7	Flavonoids	+	+	+	+	+	+	+	+	+	+
8	Saponins	-	+	-	+	-	+	-	+	+	+
9	Alkaloids	+	+	+	+	+	+	+	+	+	+
10	Tannic acid & phenolic compounds	+	+	+	+	+	+	+	+	+	+

Et – Ethanolic, Aq – Aqueous, +positive, - negative

**Table 2: Effect of CCl<sub>4</sub>, silymarin, Leaf, Whole Plant and Stem Extracts on liver function tests X**

Parameters → Groups ↓	SGPT (IU/L)	SGOT (IU/L)	ALP (IU/L)	T. Bil. (mg/dl)	D. Bil. (mg/dl)
<b>Normal Control</b>	39.44±0.90	48.28±1.32	137.80±2.62	0.60±0.02	0.18±0.01
<b>CCl<sub>4</sub></b>	648.06±8.39###	666.81±7.48###	733.89±5.72###	2.53±0.078###	0.91±0.017###
<b>Silymarin</b>	246.21±5.05***	243.87±3.99***	269.17±3.06***	0.95±0.010***	0.50±0.024***
<b>Low Dose (Stem)</b>	410.65±7.69*	440.84±3.13*	527.49±4.21*	2.01±0.016*	0.73±0.043*
<b>High Dose (Stem)</b>	369.55±5.19**	366.75±3.72**	396.70±4.06**	1.80±0.014**	0.62±0.019**
<b>Low Dose (Leaf)</b>	370.97±6.93*	368.17±5.55*	396.62±4.39*	1.75±0.027*	0.61±0.013*
<b>High Dose (Leaf)</b>	328.31±4.96***	325.51±3.90***	353.69±6.54***	1.60±0.03**	0.59±0.01**
<b>Low Dose (Whole plant)</b>	313.75±5.36***	310.95±6.54***	339.87±6.31***	1.54±0.022***	0.56±0.014***
<b>High Dose (Whole plant)</b>	281.43±5.28***	283.63±6.03***	308.58±5.55***	0.98±0.020***	0.53±0.026***

###p<0.01, when compared CCl<sub>4</sub> group with normal control group using 't' test. \*\*\*p<0.001 & \*p<0.05; when compared the groups with CCl<sub>4</sub> group, using one way ANOVA followed by Dunnett's test; (Each value represents Mean ± SEM of N=6/group).

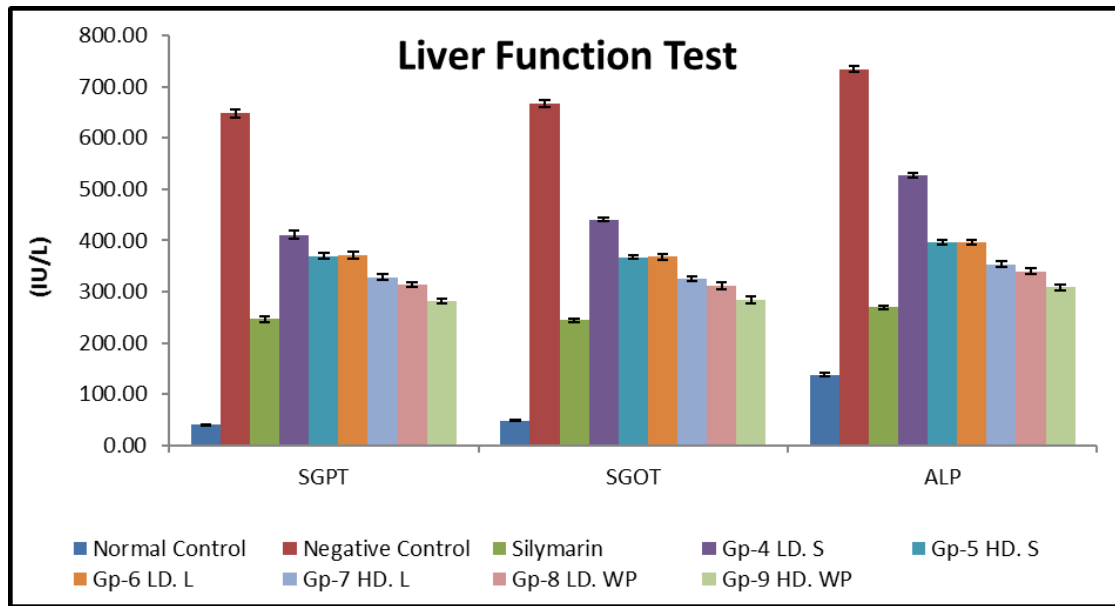


Figure 1: Effect of treatments on liver function parameters in CCl<sub>4</sub> induced acute toxicity. Column represents the Mean ± SEM, (n=6/group).

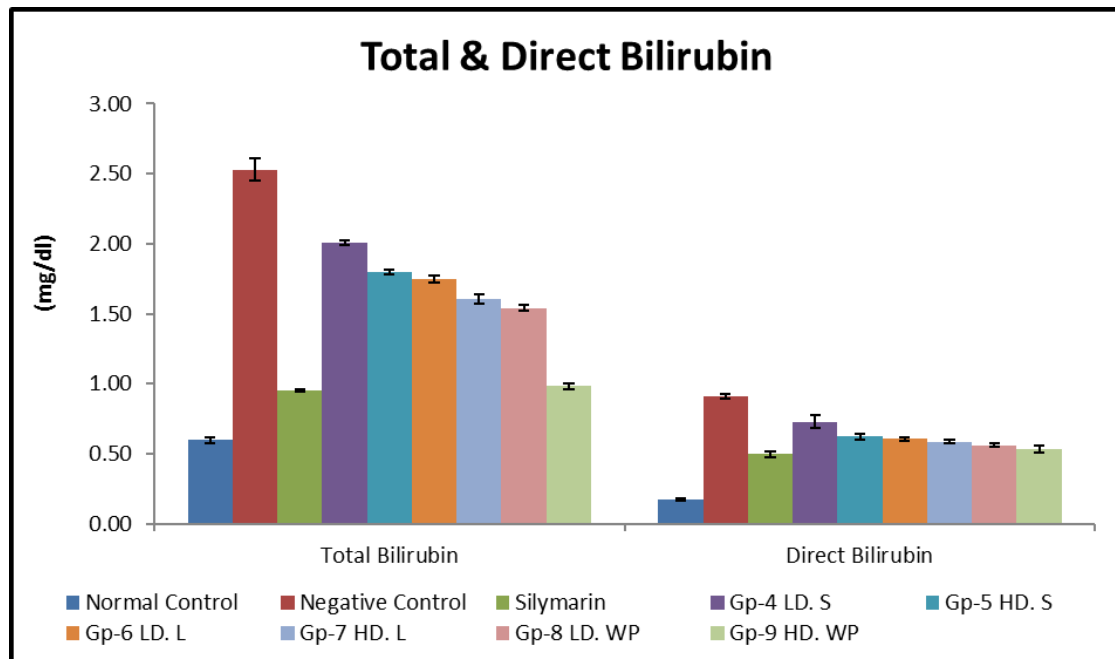


Figure 2: Effect of treatments on total & direct bilirubin CCl<sub>4</sub> induced acute toxicity. Column represents the Mean ± SEM, (n=6/group).

**DISCUSSION**

The present study to assess the hepatoprotective activity of *Inula cappa* in rats, against carbon tetrachloride as hepatotoxin proved the folklore practice of using *Inula* species against liver disorder. Carbon tetrachloride is an experimental hepatotoxicant which is widely used. It is bio transformed by the cytochrome P-450 system. By this process, it produces the trichloromethyl free radical, which in turn covalently binds to cell membranes and organelles and elicits lipid peroxidation. It also disturbs Ca<sup>2+</sup> homeostasis and finally results in cell death<sup>17</sup>.

The activities of serum marker enzymes, like SGPT, SGOT, ALP when estimated can make the assessment of liver function when liver cell plasma membrane is damaged, a variety of

enzyme which are normally located in the cytosol are released into the blood stream. Due to the structural damage of liver, the enzyme levels are increased in serum because of their location in cell cytoplasm. After damaging or injury they are released into blood circulation and raises the level of enzymes in serum<sup>18</sup>. During hepatic damage, cellular enzymes like AST, ALT and ALP present in liver cells leak into the serum, resulting in increased concentrations<sup>19</sup>. The estimation of serum marker enzymes like SGPT, SGOT, ALP in the serum is a useful quantitative marker of the extent and type of hepatocellular damage<sup>20</sup>. In extract administered group, the tendency of these enzymes to return to near normally is a clear manifestation of antihepatotoxic effects of the extract. The reduction in the levels of enzymes like SGPT and SGOT towards the normal value is an indication of regeneration process. The reduction in ALP

levels with concurrent depletion of raised bilirubin levels is suggestive of the stability of the biliary function during injury with carbon tetrachloride. Histopathological liver sections also revealed that the normal liver architecture was disturbed by hepatotoxin in carbon tetrachloride group, whereas in the liver sections of the rat treated with the aqueous extract showed the normal cellular architecture was retained and it is comparable with the standard silymarin group, hence confirming the hepatoprotective effect of whole plant extract of *Inula cappa* at the dose of 400mg/kg body weight followed by whole plant extract at dose of 200mg/kg body weight and least hepatoprotective effect was observed with stem extract. These findings suggested that *Inula cappa* extract significantly neutralized the toxic effects of carbon tetrachloride and helped in regeneration of hepatocytes.

Following the results, it can be considered that the presence of phytoconstituents such as flavonoids, sesquiterpene lactones, carbohydrates, phenolic compounds and glycosides in the aqueous extract may be responsible for the significant hepatoprotective activity. It can be concluded that the aqueous extract of whole plant (400mg/kg body weight) of *Inula cappa* exhibited the maximum hepatoprotective effect followed by the low dose of whole plant extract. The stem extract was found to have least activity as compared with leaf and whole plant extract against carbon tetrachloride induced hepatotoxicity. Efforts are in continuous progress to isolate and characterize the active principle, which is responsible for the hepatoprotective activity of this valuable medicinal plant.

## REFERENCES

- Asija R, Kumar V, Sharma AK, Hepatoprotective Activity of *Lantana Camera* against Carbon tetra Chloride Induced Hepatotoxicity in Wister Rat. International Journal of Pharmaceutical Erudition, (2015); 4(4): 1-7.
- Pramod J Hurkadale, Pournima A Shelar, Siddhalinges G Palled, Yuvaraj D Mandavkar, Ajay S Khedkar, Hepatoprotective activity of *Amorphophallus paeoniifolius* tubers against paracetamol-induced liver damage in rats. Asian Pacific Journal of Tropical Biomedicine, (2012 ): S238-S242.
- Gupta Rasna, Gupta Ankit, Singh Ram Lakhan, Hepatoprotective Activities of Triphala and Its Constituents. International Journal of Pharma Research & Review, (2015); 4(1)34-55.
- Babu B H, Shylesh B S & Padikkala J, Antioxidant and hepatoprotective effect of *Acanthus ilicifolius*. Fitoterapia, (2001);72: 272.
- Gairola Summet, Sharma CM, Rana CS, Ghildiyal SK, Suyal Sarvesh Phytodiversity (Angiosperms and Gymnosperms) in Mandal-Chopta Forest of Garhwal Himalaya, Uttarakhand, India. Nature and Science, (2010) ; 8(1):1-17.
- Mathela CS, Tiwari A, Padalia RC, Chanotia CS, C.B.Clarke. Chemical composition of *Inula cuspidata*. Indian journal of chemistry, (2008) ; 47b:1249-1253.
- Yang yan, Chemical Constituents of *Inula Cappa* Flowers, Master's Thesis, Hebei Medical University, China, 2010.
- XieHongGang, Studies on the Chemical Constituents of *Inula Cappa* DC, Master's Thesis, Peking Union, Medical College, China, 2006.
- Singh J, A study on the bark of *Inula Cappa*. Acta Ciencia Indica, (1983) ;9(1): 24.
- Anusha M, Venkateswarlu M, Prabhakaran V, Shareen Taj S, Pushpa KumariB and Ranganavakulu D, Hepatoprotective activity of aqueous extract of *Portulaca oleraea* in combination with lycopene in rats. Indian Journal of Pharmacology , (2011); 43(5): 563-567.
- Harbone JB, phytochemical methods, A guide to modern technique of plant analysis, 2nd edn, (Chapman and hall, Newyork), 1984: 85.
- Ecobichon DJ, The basis of toxicology testing, 2nd edn, (CRC press, Newyork), 1999, 43-46.
- Irwin S, Taber RI, Fox JA, Roth FE, Comparision of perfenazine an dfluphenazine enanthates in rats. Psychopharmacologia (1968) ;12: 441.
- Rekha Rajendran, Hepatoprotective activity of *Mimosa pudica* leaves against Carbontetrachloride induced toxicity. Journal of Natural Products (2009) ; 2:116-122.
- Rajasekhran A, Arivukkarasu R, Muruges S, Hepatoprotective Effect of *Adenema hyssopifolium* G. Don (Gentianaceae) in Carbon Tetrachloride-induced Hepatotoxicity in Rats. Tropical Journal of Pharmaceutical Research, April (2010) ;9(2): 157-163.
- Jendrassik L, Grof P, Quantitative determination of total and direct bilirubin in serum and plasma. Biochemistry, (1938) ;1297: 81.
- Recknagel, R.O, Glender, E.A, Walter, R.L, Mechanism of Carbon tetrachloride toxicity. Pharmacology and therapeutics, (1989);43: 139-54.
- Nuzhat Sultana, Rahila Nazam, Gross toxicities and Hepatoprotective effect of *Aloe vera* (L) BURM.F. International research Journal of Pharmacy, 2012;3(10): 108
- Ramesh Patel and Talha Jawaid, Hepatoprotective activity of aerial parts of plant extract of *Callicarpa macrophylla* in rats. Pharmacy and Pharmacology Research, April (2014) ;2(1): 1-8.
- Mitra S.K, Venkataranganna M.V, Sundaram R, Gopumadhavan S, Protective effects of HD-03, a herbal formulation against various hepatotoxic agents in rats. Ethnopharmacology Journal., (1998); 63: s181-86.

## Cite this article as:

Ajit Kiran Kaur, Sokindra Kumar, Pradeep Kumar Sharma Hepatoprotective activity of *Inula cappa* DC. aqueous extract against carbon tetrachloride induced hepatotoxicity in wistar rats. Int. Res. J. Pharm. 2017;8(1):14-19 <http://dx.doi.org/10.7897/2230-8407.08013>

Source of support: Nil, Conflict of interest: None Declared

Disclaimer: IRJP is solely owned by Moksha Publishing House - A non-profit publishing house, dedicated to publish quality research, while every effort has been taken to verify the accuracy of the content published in our Journal. IRJP cannot accept any responsibility or liability for the site content and articles published. The views expressed in articles by our contributing authors are not necessarily those of IRJP editor or editorial board members.